



# County of Sacramento

Department of Coroner  
4800 Broadway, Suite 100  
Sacramento, CA 95820-1530

Kimberly D. Gin  
Coroner

Autopsy

External Examination

**NAME:** SMITH, BRANDON

**CASE NO.** 18-03163

**POSTMORTEM DATE:** 06/07/18

**TIME:** 10:45

**INVESTIGATOR:** Caleb Shifflett

## AUTOPSY FINDINGS:

1. Sudden death with methamphetamine intoxication, while in custody of law enforcement:
  - A. Reported history of becoming unresponsive while in the backseat of a law enforcement vehicle
  - B. Methamphetamine intoxication, see Toxicology Reports
  - C. Apparent plastic "baggie" identified in stomach
2. Cutaneous and subcutaneous blunt force injuries:
  - A. No internal torso or intracranial trauma
  - B. No evidence of neck compression or asphyxia

**CAUSE OF DEATH:** Sudden death with methamphetamine intoxication, while in custody of law enforcement

*Brian Nagao*

Brian M. Nagao, M.D.  
Forensic Pathologist

Date: 6/11/2018

BMN/clk

D: 06/07/18

T: 06/08/18

**WITNESSES:**

Detective B. Robison (Badge #414), Detective K. Koppinger (Badge #914), CSI K. Vollenweider (Badge #6377), and CSI M. Bauer (Badge #6381) of the Sacramento Police Department.

**IDENTIFICATION:**

A Sacramento County Coroner's identification tag attached to the body bag zipper has the inscription "18-03163 SMITH, BRANDON". At the time of autopsy paper bags are on the hands.

**CLOTHING:**

A hospital gown is on the body. A rubber band is in the hair.

**EVIDENCE OF MEDICAL INTERVENTION:**

The left nostril has a nasopharyngeal airway tube. The chest and abdomen have electrocardiogram electrodes. Catheters are in the right and left antecubital fossae. The right wrist has a hospital identification bracelet and the left first toe and body bag have hospital tags, all of which bear the inscription "SMITH, BRANDEN (sic), MRN: 62294057, 9/20/1987".

**EXTERNAL EXAMINATION**

The body is that of a normally developed, well-nourished, 69 inch in length, 200 pound, adult male with the reported age of 30 years. The body is refrigerated, unembalmed, and well preserved. The curly, black scalp hair has a normal distribution. The conjunctivae are free of petechiae. The sclerae are white. The corneas are clear. The irides are brown. Apparent tattoos are lateral to the right and left eyes. The ears, nose, and mouth are normally developed. The external auditory canals are unremarkable. The nasal bones have no palpable fractures. The nasal septum is intact. The teeth are natural. A mustache and beard are present. The neck is free of masses, scars, and external injuries. Tattoos are on the right and left sides of the neck. The chest is symmetrical, free of deformities, and has tattoos. The right upper quadrant of the abdomen has an 8 centimeter obliquely-oriented scar. The left upper back has a 6.5 centimeter curvilinear scar. The external genitalia are those of an adult male. Both testicles are palpable in the scrotum. The anus is unremarkable. The extremities are symmetrical and are free of deformities. The medial right elbow and forearm have multiple up to 1.5 centimeter scabbed lesions. The right and left forearms have tattoos. The posterior left wrist has a 2 centimeter scar. The left hip has a 2 x 1.7 centimeter brown macule.

**EVIDENCE OF INJURY:**

Foreign material consistent with plastic "baggie" is in the stomach. The baggie is disrupted. No additional foreign material is identified in the baggie.

The right and left sides of the forehead have an 11.5 x 4 centimeter area of multiple red abrasions. The nose has scattered up to 0.5 x 0.1 centimeter red abrasions. The right cheek has a 1.2 centimeter linear red abrasion. The right side of the upper lip, inner aspect, has a 1 x 0.5 centimeter red abrasion. There are no subcutaneous hemorrhages, skull fractures, or intracranial injuries.

The midline lower abdomen has a 0.8 x 0.7 centimeter tan-red abrasion. The subcutaneous tissue of the posterior torso is reflected and demonstrates a midline upper back 6.5 x 4 centimeter area of subcutaneous hemorrhage and a left and right lower back 14 x 9.5 centimeter area of subcutaneous hemorrhage. There are no rib fractures or internal torso injuries.

The posterior right elbow has a 0.6 centimeter red abrasion and a 0.4 centimeter red abrasion. The lateral right wrist has a 3 x 1.1 centimeter area of red contusion with a posterolaterally adjacent 2.5 x 0.7 centimeter linear, brown abrasion. The posteromedial right wrist has a 1.5 x 0.5 centimeter linear, brown abrasion. The posterior left elbow has a 1.5 x 1.1 centimeter brown abrasion. The medial left forearm has a 4 x 2 centimeter group of faint red-purple contusions with focal linear abrasion. The posterolateral left wrist has a 2.7 x 1.5 centimeter irregular, brown abrasion. The anteromedial left wrist has a 1.3 x 0.3 centimeter linear, brown abrasion. The posterior left index finger has a 0.2 x 0.2 centimeter red abrasion. The posterior left third finger has a 0.4 x 0.4 centimeter red abrasion.

The posterolateral right thigh has a 3 x 0.5 centimeter group of red abrasions. The posteromedial left knee has a 1.3 x 0.6 centimeter group of red abrasions.

### INTERNAL EXAMINATION

**HEAD AND CENTRAL NERVOUS SYSTEM:** The reflected scalp is free of contusions. The calvarium and skull base are not fractured. There are no epidural or subdural hemorrhages. The 1370 gram brain is covered by thin, delicate leptomeninges with no underlying subarachnoid hemorrhage or exudate. The cranial nerves at the base of the brain are intact. The vessels of the Circle of Willis have no atherosclerosis or aneurysms. The cerebral hemispheres are symmetrical. The gyri and sulci are normal. The superficial and deep gray matter, white matter, and ventricles are unremarkable. The cerebellum and brainstem have no abnormalities.

**NECK:** A layerwise dissection of the anterior and posterior neck muscles reveals no neck hemorrhages. The hyoid bone and thyroid cartilage have no fractures. The large vessels of the neck are unremarkable. The pharynx, larynx, and trachea are free of masses and obstructing foreign bodies. The trachea has a thin layer of clear, frothy fluid. The epiglottis and vocal cords are unremarkable.

**BODY CAVITIES:** The pleural, pericardial, and peritoneal cavities have no adhesions or excess fluid collections. The diaphragm and the organs of the thorax and abdomen are in their normal anatomic locations. The subcutaneous fat of the anterior abdominal wall is 2.6 centimeters in maximum thickness.

**CARDIOVASCULAR SYSTEM:** The 390 gram heart has a smooth epicardial surface and moderate epicardial fat. The coronary ostia are normally positioned and are widely patent. The coronary circulation is right dominant, has a normal anatomic distribution, and is free of atherosclerosis. The heart is anatomically normally developed. The uniformly red-brown myocardium has no fibrosis, hemorrhages, or areas of pallor. The left ventricular wall, right ventricular wall, and interventricular septum are 1.4 centimeters, 0.3 centimeter, and 1.3 centimeters in maximum thickness, respectively. The interatrial and interventricular septa are normally developed. The fossa ovalis is closed. The endocardium is thin, translucent, and is free of mural thrombi. The papillary muscles and chordae tendineae are unremarkable. The valvular annuli are normal and have thin, pliable cardiac valves with no vegetations or calcifications. The tricuspid valve, mitral valve, pulmonic valve, and aortic valve are 11.8 centimeters, 10.6 centimeters, 7 centimeters, and 6.2 centimeters in circumference, respectively.

The thoracoabdominal aorta has a normal caliber, is intact, and has no atherosclerotic changes. The vena cava has a normal anatomic course and is free of thromboemboli.

**RESPIRATORY SYSTEM:** The 870 gram right lung and 730 gram left lung have smooth pleural surfaces and red, congested and edematous parenchyma, with no masses or areas of consolidation. The pulmonary vessels are free of thromboemboli. The bronchi have no foreign material or abnormal secretions.

**GASTROINTESTINAL SYSTEM:** The tongue has no contusions or bite marks. The serosal and mucosal surfaces of the esophagus are unremarkable. The stomach contains 110 grams of red liquid. The gastric mucosa has no ulcers or masses. The serosal surfaces and mucosal surfaces of the small bowel and colon are normal. The appendix is present. The rectum has unremarkable mucosa and contains hard stool.

**HEPATOBIILIARY SYSTEM AND PANCREAS:** The 1950 gram liver has a smooth, intact capsule and red, soft parenchyma with a nutmeg pattern and no masses. The thin-walled gallbladder has velvety mucosa and contains approximately 20 milliliters of bile and no calculi. The biliary tree is normally developed and has patent branches with normal calibers. The vessels of the porta hepatis are unremarkable. The pancreas has lobulated, tan parenchyma with no masses.

**RETICULOENDOTHELIAL SYSTEM:** The thymus is not conspicuous. The 120 gram spleen has a smooth, intact capsule and dark red, soft parenchyma. The bone marrow of the ribs is red and soft. The lymph nodes of the neck, thorax, abdomen, and pelvis are not enlarged.

**GENITOURINARY SYSTEM:** The 120 gram right kidney and 150 gram left kidney have capsules that strip easily, revealing smooth cortical surfaces. The renal parenchyma has well-defined corticomedullary junctions and no masses. The renal vessels are patent. The pelvicalyceal systems are unremarkable. The ureters have normal courses and calibers. The bladder contains 150 milliliters of urine and has tan, flat mucosa. The prostate gland has homogeneous parenchyma.

**REPRODUCTIVE SYSTEM:** The testicles have soft, tan parenchyma with no masses.

**ENDOCRINE SYSTEM:** The pituitary gland is not enlarged. The thyroid gland is free of masses. The parathyroid glands are inconspicuous. The adrenal glands have unremarkable, yellow-orange cortices and brown medullae.

**MUSCULOSKELETAL SYSTEM:** The skeletal muscles of the thorax, abdomen, and pelvis are red and soft. The ribs, clavicles, sternum, and vertebrae are unremarkable. The pelvis has no palpable abnormalities.

**TOXICOLOGY:**

Four tubes of antemortem blood, including one lavender top, two green tops, and one blue top, are received with the body. All of the tubes have hospital labels bearing the inscription "SMITH, BRANDEN (sic), MRN: 62294057, 9/20/1987". The lavender top is submitted for toxicology. The remaining specimens are retained.

Postmortem femoral blood is also submitted for toxicology. Heart blood, vitreous fluid, gastric contents, bile, urine, and liver are retained.

**RADIOLOGY:**

Postmortem X-rays of the head and chest are obtained. No fractures are seen.

**HISTOLOGY:**

Representative sections of various organs are retained. Sections are submitted for histology as follows:

Cassette 1: Left lung and left kidney

Cassette 2: Right lung and right kidney

Cassette 3: Liver and interventricular septum of heart

Cassette 4: Posterior right ventricle and left ventricle walls of heart

Cassette 5: Anterior and lateral left ventricle walls of heart

Cassette 6: Frontal lobes of brain

Cassette 7: Upper back subcutaneous hemorrhage

Cassette 8: Lower back subcutaneous hemorrhage

**MICROSCOPIC DESCRIPTION:**

Lungs:	Alveolar edema
Kidneys:	No diagnostic abnormality; no polarizable crystals
Liver:	Sinusoidal congestion; minimal steatosis
Heart:	Myocyte enlargement
Brain:	No meningoencephalitis, neoplasm, infarction, or hemorrhage
Back:	Hemorrhages consisting predominantly of RBCs

BMN/clk

D: 06/07/18

T: 06/08/18

CASE FILE  
SACRAMENTO COUNTY CORONER

# 18-03163

Type: Undetermined

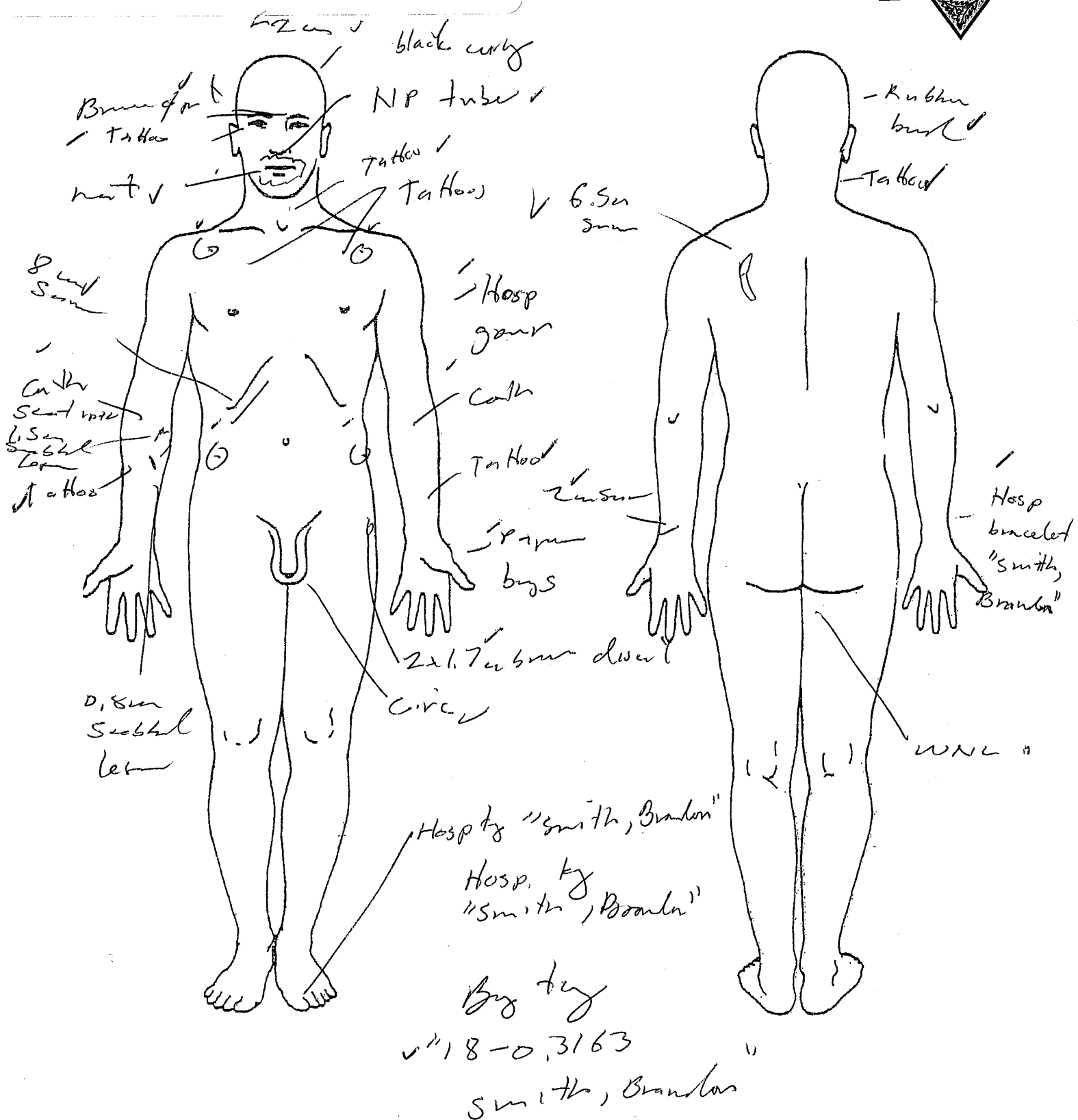
SMITH, BRANDON

Doctor: NAGAO, Brian

30 Years

Male

Deputy: SHIFFLETT, Caleb



Forensic Pathologist: Brian Nagao



18-004501 (0004)



# Sacramento County District Attorney's Office

Stephen J. Grippi  
Chief Deputy

Michael A. Neves  
Assistant District Attorney

Edward M. Pollock  
Laboratory Director

**ANNE MARIE SCHUBERT**  
District Attorney

June 19, 2018

Sacramento County Coroner  
4800 Broadway, Suite 100  
Sacramento, CA 95820

**LAB NO:** 18-004501  
**REQUEST NO:** 0004  
**AGENCY NO:** COR-18-003163



**NAME:** Smith, Brandon

## Toxicology Report

Submission: 003

Source: Smith, Brandon

Sample Type: blood

Date Received: 6/18/2018

Origin: femoral

### Drug Classes Evaluated

amphetamine, benzodiazepines, benzoylcegonine (cocaine metabolite), carisoprodol, methadone, methamphetamine, opiates, oxycodone, zolpidem, tetrahydrocannabinols.

Drugs Confirmed	Concentration	Estimated Uncertainty (99.7% confidence at k=3)	Analyst
methamphetamine	4289 ng/mL	±729 ng/mL	Triebold, Craig
amphetamine	48 ng/mL	±10 ng/mL	Triebold, Craig

Presumptive testing indicates tetrahydrocannabinols may be present. If confirmation is needed, please contact the laboratory.

Craig Triebold, Criminalist

June 19, 2018

Date

LABORATORY OF FORENSIC SERVICES  
4800 Broadway, Suite 200 - Sacramento, CA 95820  
(916) 874-9240 FAX (916) 321-2230  
www.sacda.org

This report contains the results and conclusions of the signing analyst.  
Supporting examination documentation is maintained in the case file.

*Matthew Nakayama*  
6/19/2018

Technical Reviewer  
Matthew Nakayama, Criminalist

Date

*Chris Fogelberg*  
6/19/2018

Administrative Reviewer  
Chris Fogelberg, Criminalist

Date



18-004501 (0001)



# Sacramento County District Attorney's Office

**ANNE MARIE SCHUBERT**  
District Attorney

Stephen J. Grippi  
Chief Deputy

Michael A. Neves  
Assistant District Attorney

Edward M. Pollock  
Laboratory Director

June 11, 2018

Sacramento County Coroner  
4800 Broadway, Suite 100  
Sacramento, CA 95820

**LAB NO:** 18-004501  
**REQUEST NO:** 0001  
**AGENCY NO:** COR-18-003163



**NAME:** Smith, Brandon

### Blood Alcohol Report

Submission: 001

Source: Smith, Brandon

Sample Type: blood

Ethanol Result: None Detected

Date Received: 6/8/2018

Date Analyzed: 6/11/2018

Origin: antemortem

**NOTE:**

Name on tube: "Smith, Branden" and "DOE, JO URI" (Label 1)  
"Smith, Brandon" (Label 2)

Date on tube: 6/6/18

Time on tube: Not indicated

Tube type: Lavender

June 11, 2018

Kristine Myhre, Criminalist  
Forensic Alcohol Analyst

Date

  
6/11/2018

Technical Reviewer  
Allyson Avina, Criminalist

Date

  
6/11/2018

Administrative Reviewer  
Sara Porter, Criminalist

Date

LABORATORY OF FORENSIC SERVICES  
4800 Broadway, Suite 200 - Sacramento, CA 95820  
(916) 874-9240 FAX (916) 321-2230

[www.sacda.org](http://www.sacda.org)

This report contains the results and conclusions of the signing analyst.  
Supporting examination documentation is maintained in the case file.

18-004501 (0002)



# Sacramento County District Attorney's Office

Stephen J. Grippi  
Chief Deputy

Michael A. Neves  
Assistant District Attorney

Edward M. Pollock  
Laboratory Director

**ANNE MARIE SCHUBERT**  
District Attorney

June 14, 2018

Sacramento County Coroner  
4800 Broadway, Suite 100  
Sacramento, CA 95820

**LAB NO:** 18-004501  
**REQUEST NO:** 0002  
**AGENCY NO:** COR-18-003163



**NAME:** Smith, Brandon

## Toxicology Report

Submission: 001

Source: Smith, Brandon

Sample Type: blood

Date Received: 6/8/2018

Origin: antemortem

### Drug Classes Evaluated

amphetamine, benzodiazepines, benzoylcegonine (cocaine metabolite), carisoprodol, methadone, methamphetamine, opiates, oxycodone, zolpidem, tetrahydrocannabinols.

Drugs Confirmed	Concentration	Estimated Uncertainty (99.7% confidence at k=3)	Analyst
methamphetamine	3991 ng/mL	±678 ng/mL	Triebold, Craig
amphetamine	39 ng/mL	± 8 ng/mL	Triebold, Craig

### NOTE:

Due to the limited sample quantity, basic and acidic-neutral drug assays were not performed. Presumptive testing indicates tetrahydrocannabinols may be present. Confirmation not performed in order to preserve the remaining sample.

Tube 001-01

Name on tube: "Smith, Branden" and "DOE, JO URI" (Label 1)  
"Smith, Brandon" (Label 2)

Date on tube: 6/6/18

Time on tube: Not indicated

Tube type: Lavender

LABORATORY OF FORENSIC SERVICES  
4800 Broadway, Suite 200 - Sacramento, CA 95820  
(916) 874-9240 FAX (916) 321-2230  
www.sacda.org

This report contains the results and conclusions of the signing analyst.  
Supporting examination documentation is maintained in the case file.

*Craig Triebold*

Craig Triebold, Criminalist

June 14, 2018

Date

*Chris Fogelberg*  
6/14/2018

Technical Reviewer

Date

Chris Fogelberg, Criminalist

*Michael Toms*  
6/14/2018

Administrative Reviewer

Date

Michael Toms, Supervising Criminalist





**SACRAMENTO COUNTY  
CORONER**

**Final Case Summary**

On 06/06/2018, the Sacramento County Coroner's Office received a report of the decedent's death from Sutter Medical Center - Sacramento. As required by Government Code, Section 27491, an inquiry was made into the death. The decedent was removed to this office where an examination was performed by Brian Nagao, M.D.. The cause of death was determined to be:

Sudden death with methamphetamine intoxication, while in custody of law enforcement

Other Significant Conditions: None

On the afternoon of 06/06/18, the decedent was transported in a motor vehicle by law enforcement officers. At some point during transport, the decedent became unresponsive. He was subsequently transported to Sutter Medical Center Sacramento where he was pronounced deceased at 1429 hours. Toxicology testing revealed the presence of methamphetamine in the decedent's system. The autopsy findings were consistent with the death being caused by methamphetamine intoxication.

Based on the circumstances and cause of death, the manner will be listed as Accident.